

craniofacial macrosomia and distraction osteogenesis

authors

Karen Federici APRN, pediatric intensive care

Kristin Mikolajewski APRN, pediatric intensive care

Jessica Whitlock APRN, plastic surgery

Pediatric Clinical Clips presented by Dayton Children's Advanced Practice Professionals provides quick reviews of common pediatric conditions.

Dayton Children's is the region's pediatric referral center for a 20-county area. As the only facility in the region with a full-time commitment to pediatrics, Dayton Children's offers a wide range of services in general pediatrics as well as in 35 subspecialty areas for infants, children and teens. We welcome your inquiries about services available — call 937-641-3666 or email marketing@childrensdayton.org.

background

Craniofacial macrosomia (CFM) includes a variation of congenital growth deformities causing underdevelopment of the facial structures. Examples of CFM include mandibular hypoplasia, maxillary hypoplasia, zygomatic hypoplasia, micrognathia and glossoptosis. CFM is the second largest birth defect occurring in approximately 1 in 5500 births. The cause of CFM is not fully understood but contributing factors include genetics, environmental exposures and folic acid deficiency.

Treatment varies based on the degree of airway obstruction. In life-threatening circumstances, distraction osteogenesis (DO) is used to enlarge the oral and nasal pharyngeal cavity in an effort to relieve the obstruction. The facial bones are surgically fractured, or segmented, and then gradually separated over the course of 2-3 weeks with the use of a distraction device. With each distraction (typically 1 mm per day), calluses are formed between the bone segments which eventually mineralize into new bone. Benefits of surgery include avoidance of tracheostomy or ability to decannulate a child previously requiring a tracheostomy. Additional outcomes include resolution of obstructive sleep apnea and improved facial symmetry.

case discussion

distraction osteogenesis

There are two approaches to DO: internal and external. Internal devices are less cumbersome and better tolerated by the neonatal population. External devices are more cumbersome but offer better traction and a lower rate of regression. Below are two examples of DO that are used by the plastic surgery team at Dayton Children's.

Maxillary distraction: Maxillary distraction is performed in children with severe midface hypoplasia. Maxillary advancement via external distraction involves the use of a product named Rigid Extraction Device (RED). The procedure involves a LeForte osteotomy which separates the maxilla and/or zygomatic bones to allow forward advancement. The RED device is attached to the segmented bones and wired to a halo apparatus that is attached to the cranium. Distraction involves daily turning of external pins that are attached to the wires and advance the maxilla. Daily distraction continues until the desired outcome is achieved (typically 2-3 weeks). Assessment of outcome includes clinical assessment, radiographic films and sleep study. The distractor device stays in place for approximately 6 to 8 weeks to allow consolidation of the bone. The patient then returns to the operating room for removal of the distraction device.

Mandibular distraction: Mandibular distraction is performed for children with severe micrognathia and glossoptosis. Mandibular distraction via internal device involves fracturing of the mandible bone and placement of the device through an incision in the submandibular area (below the inferior border of the mandible). The device is buried underneath the skin with only two small distractor rods protruding out from behind the jaw. The distractor rods are turned two or three times to achieve the desired outcome. The distractor device stays in place for approximately 6 to 8 weeks to allow consolidation of the bone. The patient then returns to the operating room for removal of the distraction device. This procedure is ideal for the neonatal population as it allows for normal breast and bottle feeding.

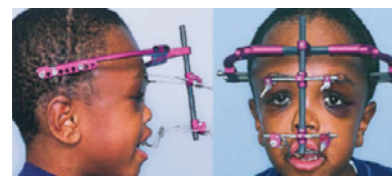


Figure 1. The RED II Distraction System. Image from www.klsmartin.com

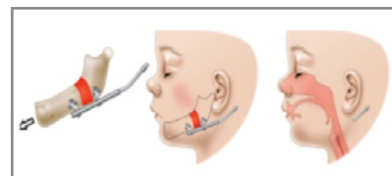



Figure 2. Internal mandibular distraction. Image from Royal Children's Hospital.

featured providers



Christopher Gordon, MD, FACS, FAAP
plastic surgery



Salim Mancho, DO,
plastic surgery

a team approach

Dayton Children's offers specialized care for children with CFM in the plastic surgery department led by Christopher Gordon, MD, and Salim Mancho, DO. Dr. Gordon has performed more than 600 mandible and mid-face osteotomy surgeries using the RED II device—more than any other doctor in the world. Families travel across the country for the expertise, while a team of more than 25 professionals from plastic surgery, anesthesia, surgical services, PICU and respiratory therapy offers specialized care for each family and their unique set of needs.

references

Jabs, E.W. (2003). The genetics of craniosynostosis in Mooney, M.P. & Siegel, M.E. (Eds.), *Understanding craniofacial anomalies* (125-146). New York: John W. Wiley and Sons.

Khansa, I., Hall, C., Madhoun, L. L., Splaingard, M., Baylis, A., Kirschner, R. E., & Pearson, G. D. (2017). Airway and Feeding Outcomes of Mandibular

Distraction, Tongue-Lip Adhesion, and Conservative Management in Pierre Robin Sequence. *Plastic and Reconstructive Surgery*, 139(4). doi:10.1097/prs.0000000000003167

KLS Martin. Rigid external distraction: RED II System in Distraction Osteogenesis. Retrieved from http://www.klsmartin.com/fileadmin/Inhalte/Downloads_Prospekte/Osteosynthese_CMF_Bio/90-791-02-07_RED_II.pdf

Royal Children's Hospital (2012). Jaw distraction mandibular distraction osteogenesis. Retrieved from http://www.rch.org.au/kidsinfo/fact_sheets/Jaw_distraction_mandibular_distraction_osteogenesis/

Zenha, H., Azevedo, L., Rios, L., Pereira, A., Pinto, A., Barroso, M., & Costa, H. (2012). Bilateral Mandibular Distraction Osteogenesis in the Neonate with Pierre Robin Sequence and Airway Obstruction: A Primary Option. *Craniofacial Trauma and Reconstruction*, 05(01), 025-030. doi:10.1055/s-0031-1300960

authors



Karen Federici, APRN
pediatric intensive care



Kristin Mikolajewski, APRN
pediatric intensive care



Jessica Whitlock, APRN
plastic surgery